



**DATE CLINICAL BACKGROUND & STUDY DETAILS**

4.2.26

**PATIENT**

Daisy Forsyth

**SPECIES**

Canine

**BREED**

Jack Russell Terrier

**SEX**

FS

**AGE**

12.20.16

**WEIGHT**

23lbs

**INTERPRETED BY**

Maggie Machen Lamy,  
DVM, DACVIM  
(Cardiology)

**HOSPITAL NAME**

Warm & Fuzzy VC

**REFERRING VET**

Dr. Pleasanton

**INVOICE**

47410

**History:** Has been coughing/wheezing for ~two weeks now. Grade 2-3 heart murmur.  
**CXR:** 1. Moderate cardiomegaly and likely concurrent left atrial enlargement, consistent with myxomatous valve degeneration or cardiomyopathy. There is no evidence of venous congestion or cardiogenic pulmonary edema. 2. Bronchial pulmonary pattern. DDx: Age-related change vs chronic bronchitis. 3. Mainstem bronchial narrowing/collapse likely due to left atrial enlargement and bronchomalacia.  
**Current medications:** Pimobendan 5mg Quad tablet give 1/2 tablet by mouth 2 times a day. (0.5mg/kg PO split into 2 times daily)  
**Blood Pressure:** 160mmHg  
**Sedation used:** Not required to complete full diagnostic ultrasound.  
**STAT:** Offered and declined.  
**Imaging performed by:** Stephanie Warga RDCS, RVT.

**ECHOCARDIOGRAM FINDINGS**

2D, m-mode, color flow and doppler imaging is available. Mild diffuse thickening of mitral valve leaflets with minimal prolapse into the left atrial lumen. Mild mitral regurgitation with mild left atrial dilation (LA:Ao <1.6). Normal LV diameter with adequate myocardial function. The tricuspid valve appears mildly thickened with mild tricuspid regurgitation. TR velocity indicative of early pulmonary arterial hypertension. Mild right heart enlargement. The pulmonic and aortic valves are normal in morphology and mobility. Normal pulmonic and aortic outflow velocities with laminar flow. No obvious aortic and trace pulmonic insufficiency. No pericardial or pleural effusion noted. No obvious cardiac masses.

**CARDIAC CHART**

CANINE CARDIAC PARAMETERS	MR VMAX (m/s)	TR VMAX (m/s)	LA/AO (Boon method)	LA/AO (Heart Base; Swe)	FS (%)	EF (%)	EPSS (cm)
<b>NORMAL PARAMETER</b>	4.5-5.5	<2.7	1.3	<1.6	28-40	40-100	<0.6
<b>PATIENT</b>	6.0	3.0	NM	1.4	56	87	NM
CANINE CARDIAC PARAMETERS	HR (BPM)	AV VMAX (m/s)	PV MAX (m/s)	BODY WEIGHT (kg)	LA 2D short axis Base view (cm)	LVIDd Avg; 2D and m-mode short axis (cm)	LVIDs Avg; 2D and m-mode short axis (cm)
<b>NORMAL PARAMETER</b>	50-100	0.7-1.7	0.7-1.6	BELOW	BELOW	BELOW	BELOW
<b>PATIENT</b>	107	1.8	1.3	10.4	2.4	3.0	1.5
*Normal chamber parameters expressed as a mean value (SD)				3	1.27 (5.3)	2.46 (2.46)	1.36 (5.5)
<b>BODY WEIGHT DEPENDENT PARAMETERS</b>				5	1.40 (4.5)	2.74 (5.2)	1.60 (4.7)
*Note: All measurements based upon multi-modal images and methods. An average value is reported.				10	1.50 (3.8)	3.27 (3.5)	2.06 (3.1)
				15	1.83 (2.0)	3.71 (2.4)	2.43 (2.1)
				20	2.02 (1.9)	4.14 (2.2)	2.80 (2.0)
				25	2.18 (2.4)	4.48 (2.9)	3.10 (2.5)
				30	2.33 (3.3)	4.83 (3.9)	3.39 (3.4)
				35	2.48 (4.3)	5.17 (5.0)	3.69 (4.5)
				40	2.62 (5.2)	5.48 (6.1)	3.96 (5.4)
				50	2.88 (7.1)	6.07 (8.3)	4.46 (7.4)

Adapted from June Boon, Veterinary Echocardiography, 1998  
Rishniw M and Hollis NE, J Vet Intern Med 2000; 14:429-435  
Hansson et al, Vet Rad and Ultrasound 2002  
Bonagura et al. Echocardiography: principles of interpretation, Vet Clin North Am 15:1177, 1995

### **INTERPRETATION OF THE FINDINGS & FURTHER RECOMMENDATIONS**

Chronic degenerative valve disease causing mild mitral and tricuspid regurgitation. Lack of significant left atrial enlargement indicates the current risk for complication is low. Mild pulmonary hypertension is noted, which is likely developing secondary to the cough/airway disease. No concurrent issues such as systolic dysfunction are noted in this study.

Given these findings, the cough is certainly non-cardiogenic in origin. Respiratory disease is likely, and screening chest radiographs may be helpful as a baseline. If the cough is poorly controlled/progresses long term, this can certainly lead to worsening of PAH. Clinical signs of significant PAH include exertional dyspnea/collapse. It is important to note that PAH does not cause the cough; rather, the cough leads to PAH. Cough control is recommended lifelong (hydrocodone, intermittent anti-inflammatory prednisone, fluoroquinolone for acute flare up, etc.). Mild pulmonary hypertension does not warrant Sildenafil therapy; however, monitoring for progressive pressure elevation and/or associated clinical signs is advised.

In a dog without significant chamber enlargement, typically no cardiac medications are indicated. That being said, the patient is already on Pimobendan which can decrease chamber dimensions, and it is reasonable to continue the medication. Assessment of progression in the future will help predict long term prognosis, which is highly variable with stage B1 disease. Many B1 dogs will remain asymptomatic with slow progression for years to come. Concurrent airway disease must be approached separately, with symptom management as discussed.

Omega fatty acid supplementation and mild salt restriction may be of some long-term benefit. Monitor for development of a cough, labored breathing, exercise intolerance or collapse episodes.

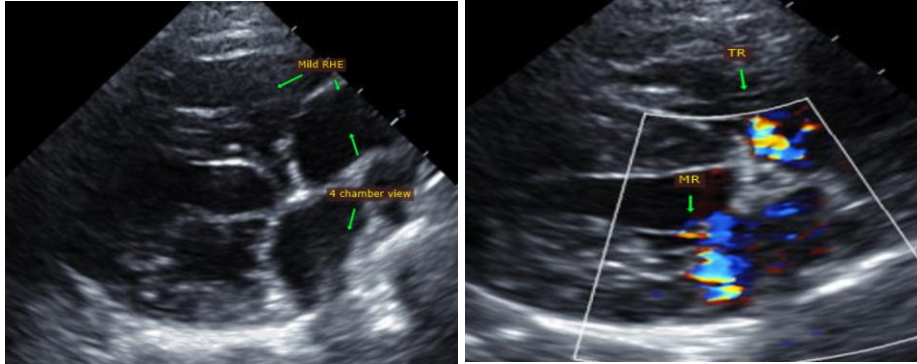
Anesthetic risk is considered mild if needed. Cardiac protective drug choices (opioid/benzodiazepine premedication, propofol or alfaxalone induction, isoflurane gas) are recommended. **Pre-oxygenate for 5-10 minutes prior to induction.** Monitor for arrhythmias, hypotension, and hypoxia both intra and post-operatively and intervene as necessary. Mild IV fluid restriction is recommended to avoid fluid overload. Avoid heart rate stimulating drugs such as atropine unless clinically indicated.

### **PLAN**

Continue Pimobendan 0.3mg/kg PO q12h. Further cough workup as discussed.

Recommend conservative monitoring with a recheck echocardiogram in 6 months to assess rate of progression, sooner if additional clinical signs develop in the interim.

## IMAGES



**The information and recommendations provided are based on the images presented by the referring veterinarian. No evaluation can be communicated regarding pathology that was not visible in the image/video clips provided.**

Thank you for this referral. This report was generated using transcription software, and minor dictation errors may be present. If the clinical or image interpretation does not parallel your findings or if I can be of any further assistance, please contact me.

**Maggie Machen Lamy, DVM**

**Diplomate of the American College of Veterinary Internal Medicine (Cardiology)**

**info@sonopath.com**